

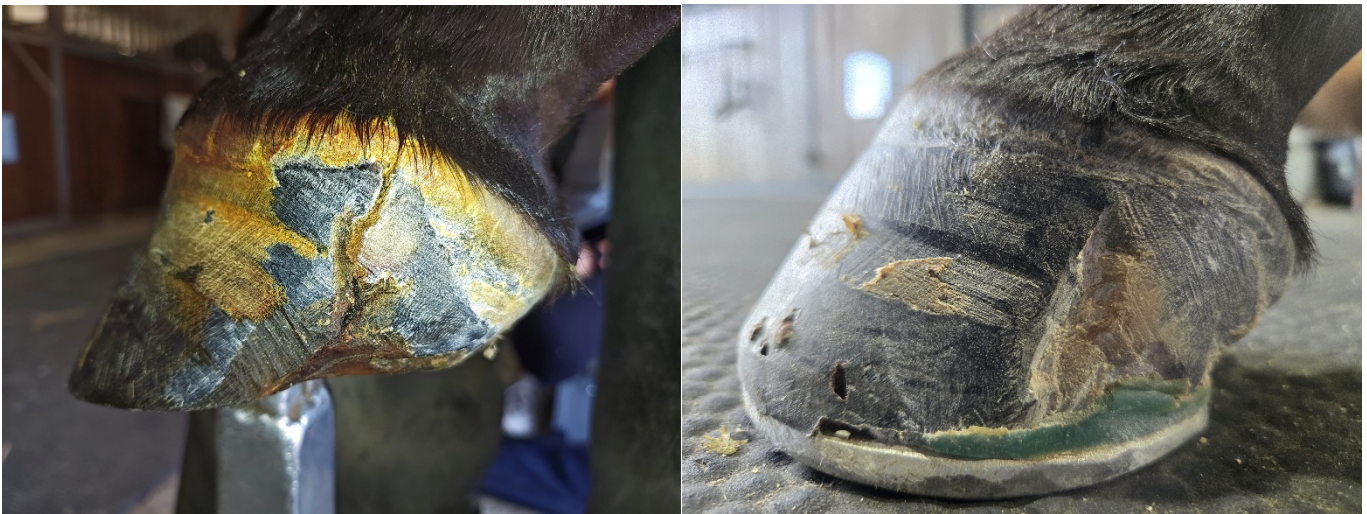

## VETERINARY REPORT

**HORSE: XXXXXX**  
**MICROCHIP: 98510001220XXXX**  
**DATE OF EXAMINATION: 19<sup>TH</sup> DEC 24**  
**PLACE: XXXXXXXXXXXX THOROUGHBREDS**

### Clinical Examination:

The colt presented sound with no detectable digital pulse and no capsular heat.



**XXXXXX R FR MED HOOF 31<sup>ST</sup> OCT 24**

**XXXXXX R FR MED HOOF 18<sup>TH</sup> DEC 24**

The medial left front quarter crack has grown considerably with approximately 10mm of wall growth from the coronary evident.

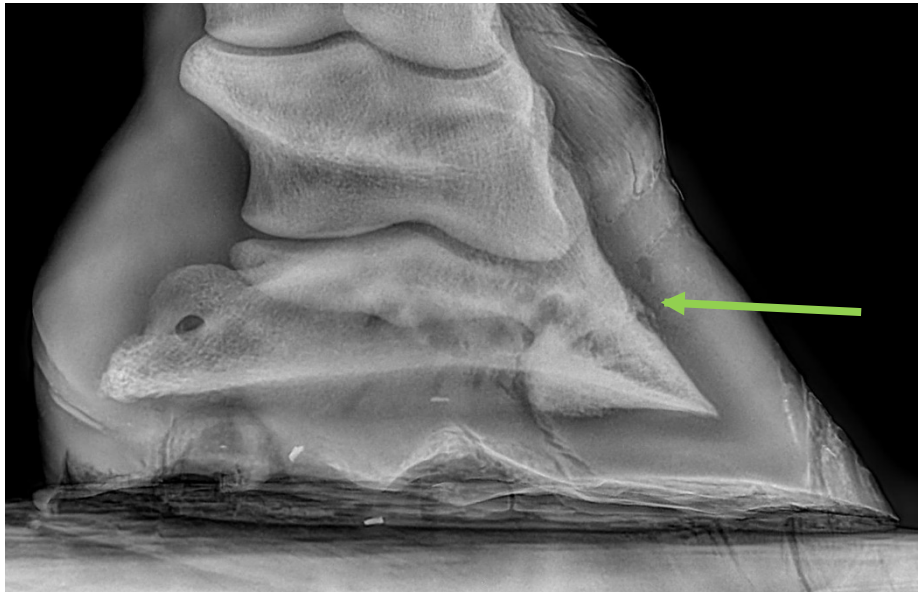
The medial quarter is now stable on palpation with no discomfort evident.

### Radiographic Examination:

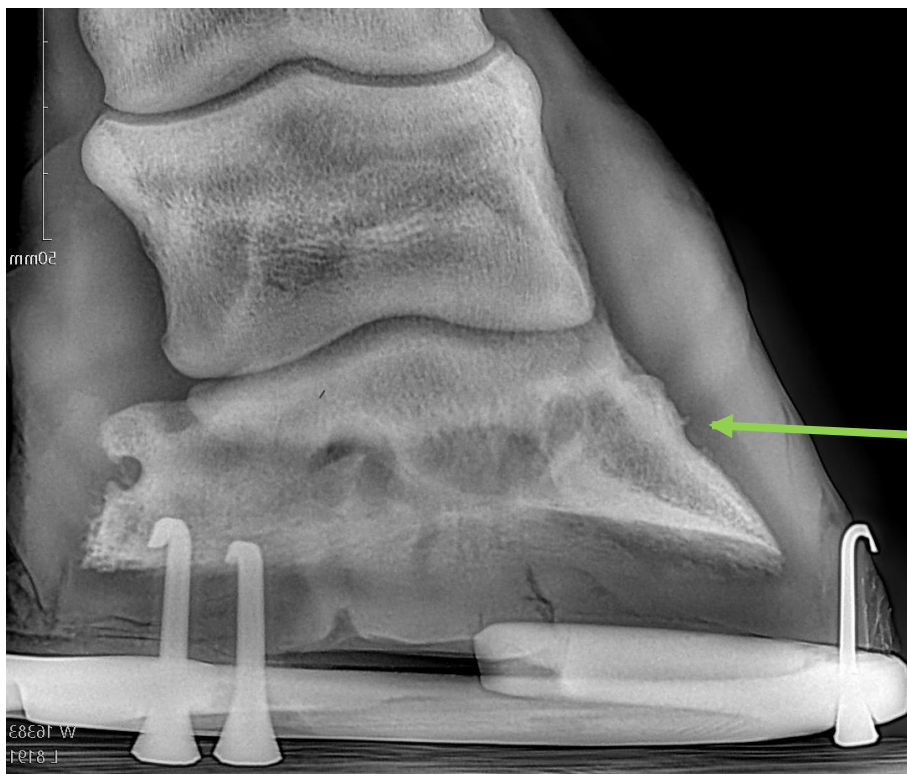Lateral radiographs show the pedal axis aligned with a mild positive pedal angle.

Dorsopalmar radiographs show the pedal column medial difference reduced from 5.1mm to 1.3mm

The medial P3 avulsion fracture has resolved as shown below.



XXXXXX R FR DP 35 DEG 31<sup>ST</sup> OCT 24



XXXXXX R FR DP 35 DEG 19<sup>TH</sup> DEC 24

**Comments:**

The pedal angle and pedal axis have been corrected with the frog movement now stabilised.

The resolution of the avulsion fracture indicates positive internal capsular resolution.

The quarter cracks have grown down well indicating the capsule is supported correctly.

**Recommendations:**

Initiate hand walking twice daily for 30mins.

Pack the resection daily with the antibiotic pack.

Re-evaluate in 5 days.

Feed **Total Gold at 4 x scoops** once per day.

Please do not hesitate to contact me anytime if you have any further queries,

Yours Sincerely,

A handwritten signature in dark ink, appearing to read 'A. Watts', is written on a light-colored background.

Dr Andrew Watts B.V.Sc.