

**Dr Andrew Watts BVSc
Equine Veterinarian
422 Grandview Rd.
Pullenvale Qld 4069
Australia: 0406 060 960**



VETERINARY REPORT

**HORSE: XXXXXXXX
CHIP: 9851000XXXXXX
DATE OF EXAMINATION: 10TH JAN / 29TH FEB 24
PLACE: XXXXXXXXX FARM**

Clinical Examination:

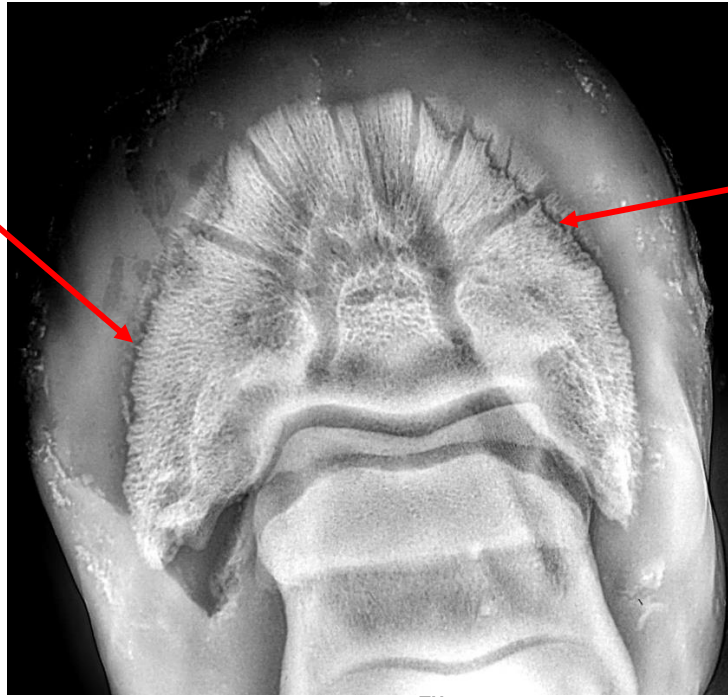
The filly presented sound at the walk however with a mild bilateral digital pulse.

The left lateral sole has delaminated with healthy new sole re growth.

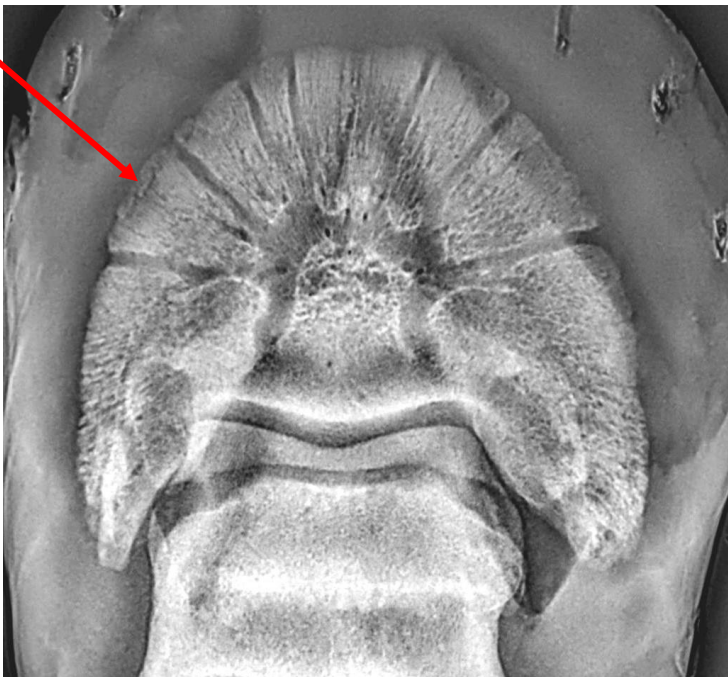
Radiographic Examination:

Left Front Hoof: Dorso ventral radiographs from today show considerable resolution of the Type IV solar margin fractures evident medially and laterally on the 10th of Jan 24 as indicated by the red arrows below. One medial fracture remains as indicated.

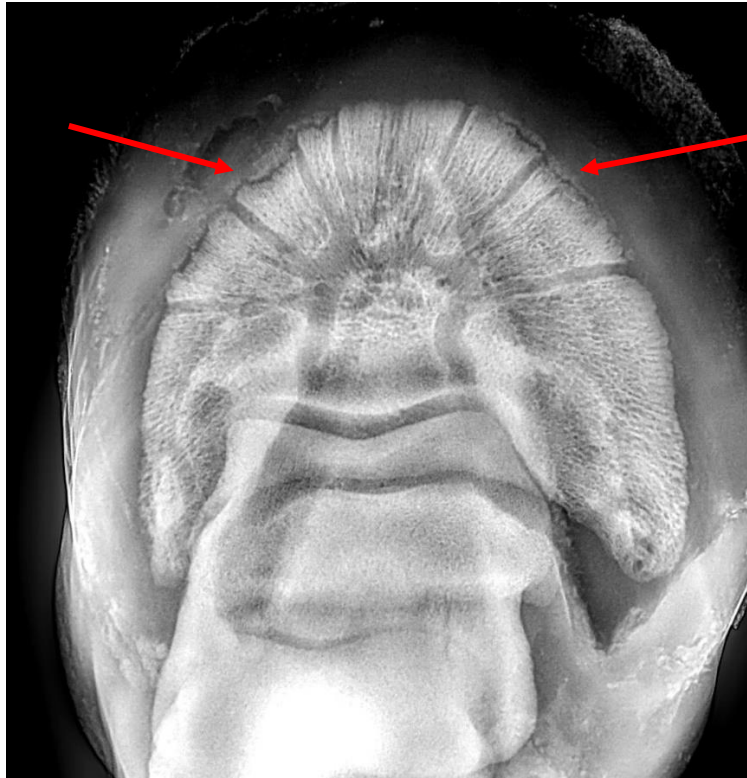
Right Front Hoof: Dorso ventral views show again significant resolution of both medial and lateral type IV fractures. An additional fracture can be identified medially.



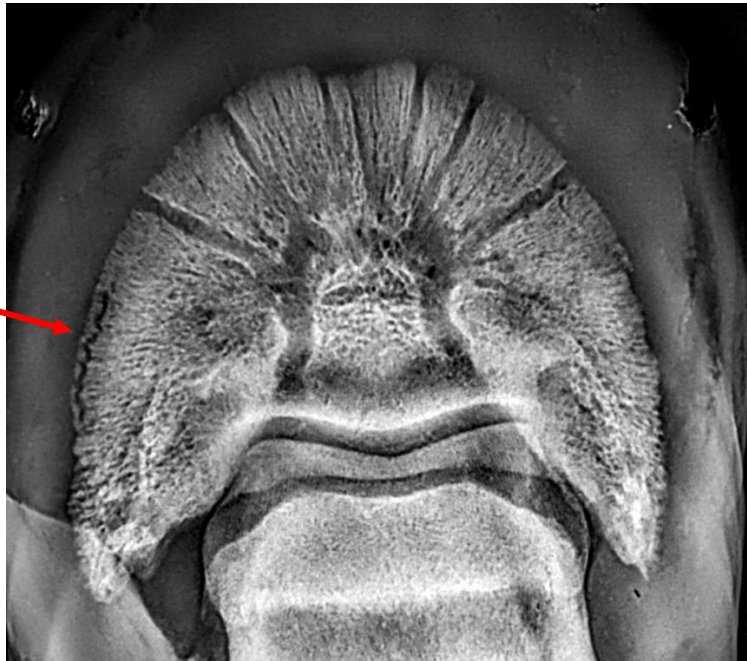XXXXXX L FR 10TH JAN 24



XXXXXX L FR 29TH FEB 24



XXXXXX R FR 10TH JAN 24



XXXXXX R FR 29TH FEB 24

Comments:

Fracture resolution times have been unexpectedly short.

Recommendations:

Continue daily bandage changes applying topical iodine as directed for the next 5 days.

Shoe with alloys seated out to circumference without side clips and apply Sole pack CS once soles are hardened.

The filly should remain in box rest walking 20 mins twice daily until shod and re-evaluated 7 days post shoeing.

Continue Bone Gold at 3 x scoops once per day.

Please do not hesitate to contact me if there are any changes to the filly's comfort level or if you have any questions,

Yours Sincerely,

A handwritten signature in dark ink, appearing to read 'Andrew Watts', is centered on a light pink rectangular background.

Dr Andrew Watts B.V.Sc.