

**Dr Andrew Watts BVSc
Equine Veterinarian
422 Grandview Rd.
Pullenvale Qld 4069
Australia: 0406 060 960**



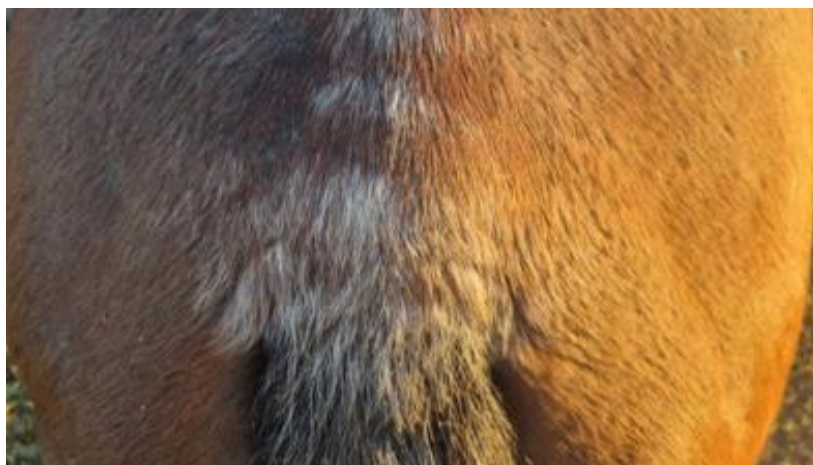
VETERINARY REPORT

**HORSE: PENNY
DESCRIPTION: 14YO BAY STOCKHORSE MARE
DATE OF EXAMINATION: 16TH SEP 23 / 18TH DEC 23
PLACE: EQUINE PODIATRY FACILITY PULLENVALE**

Clinical Examination:



PENNY 16TH SEP 23



PENNY 18TH DEC 23

Re-examination of the mare shows considerable resolution of all associated lesions as per photographs. The sub dermal infection has resolved with significant follicular regrowth over the tail base, rump, neck and face as per photographs.

The mare has gained weight, appears comfortable and the seborrheic smell has dissipated.

Comments:

Remarkable recovery from a debilitating chronic skin disease.

Recommendations:

Continue TOTAL GOLD supplementation and utilising the light weatherproof rug.

Please do not hesitate to contact me if you have any further queries,

Yours Sincerely,

A handwritten signature in dark ink, appearing to read 'A. Watts', is centered on a light pink rectangular background.

Dr Andrew Watts B.V.Sc.