

**Dr Andrew Watts BVSc
Equine Veterinarian
422 Grandview Rd.
Pullenvale Qld 4069
Australia: 0406 060 960**



VETERINARY REPORT

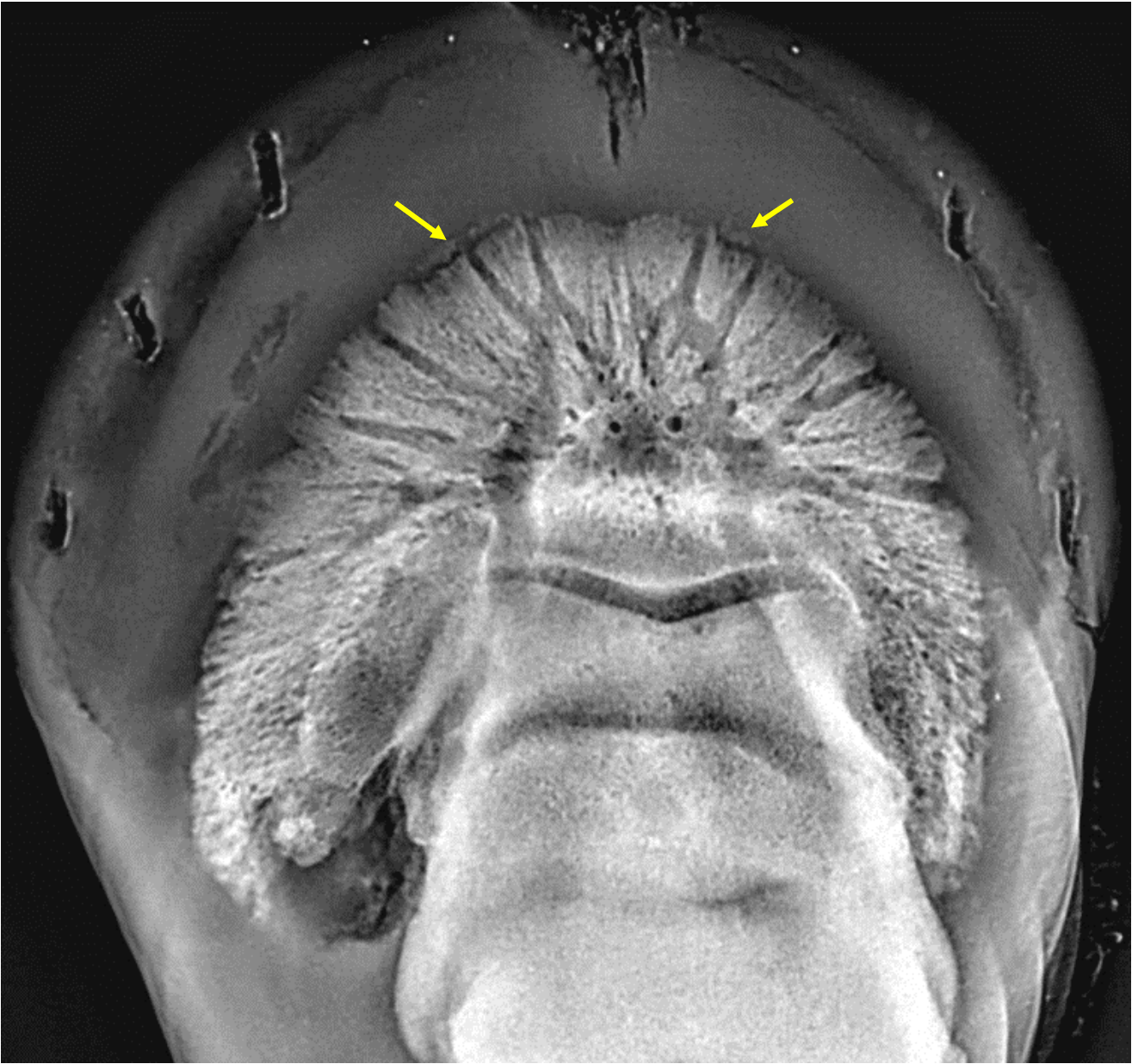
**HORSE: XXXXXXXXXXXX
CHIP: 985100012XXXXXX
DATE OF EXAMINATION: 7TH DEC 23
PLACE: XXXXXXXX XXXXXXXXXXXX**

Clinical Examination:

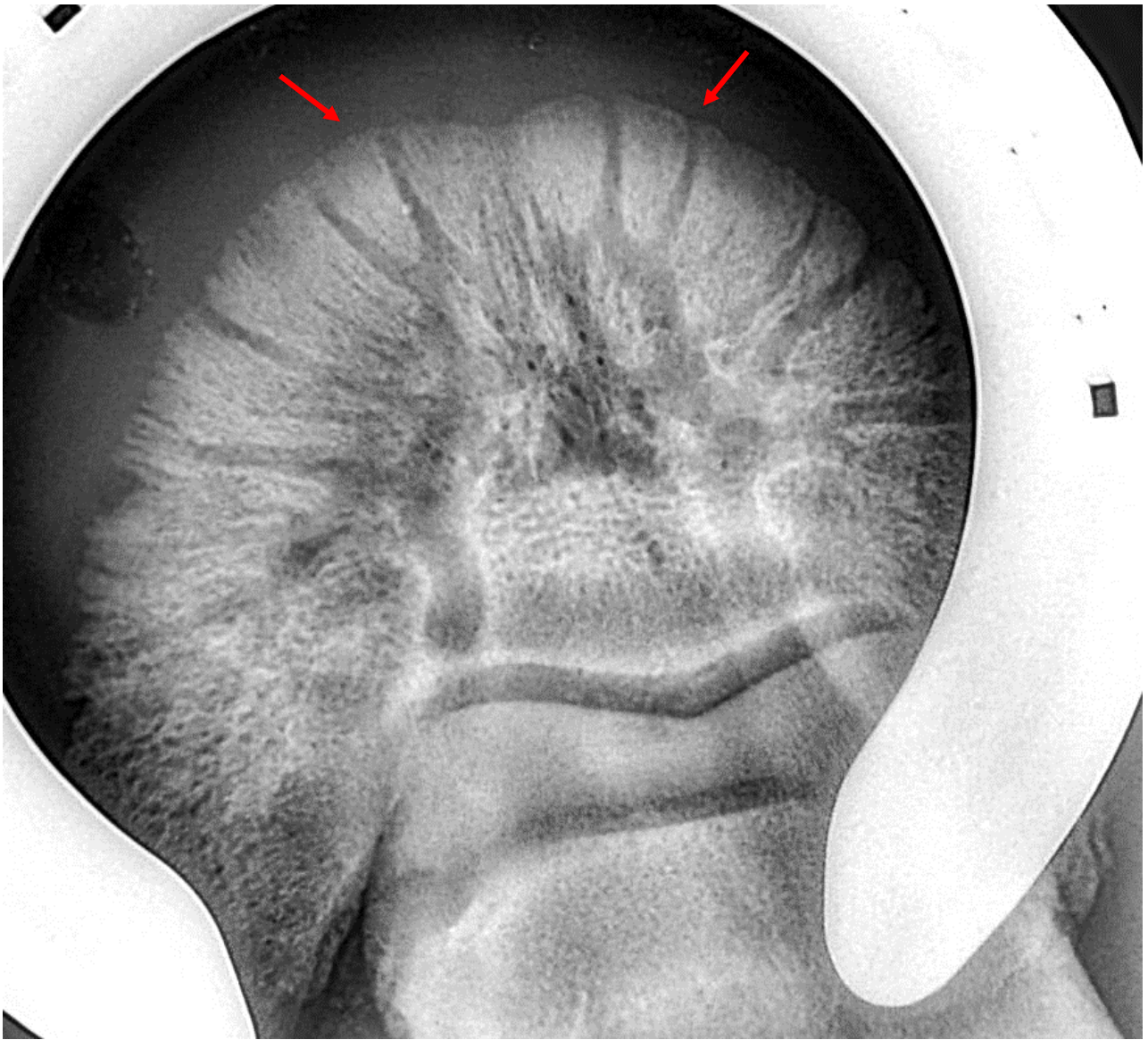
The horse presented sound at the trot and is in work with no heat or digital pulse evident bilaterally 12 weeks post original radiographs.

Radiographic Examination:

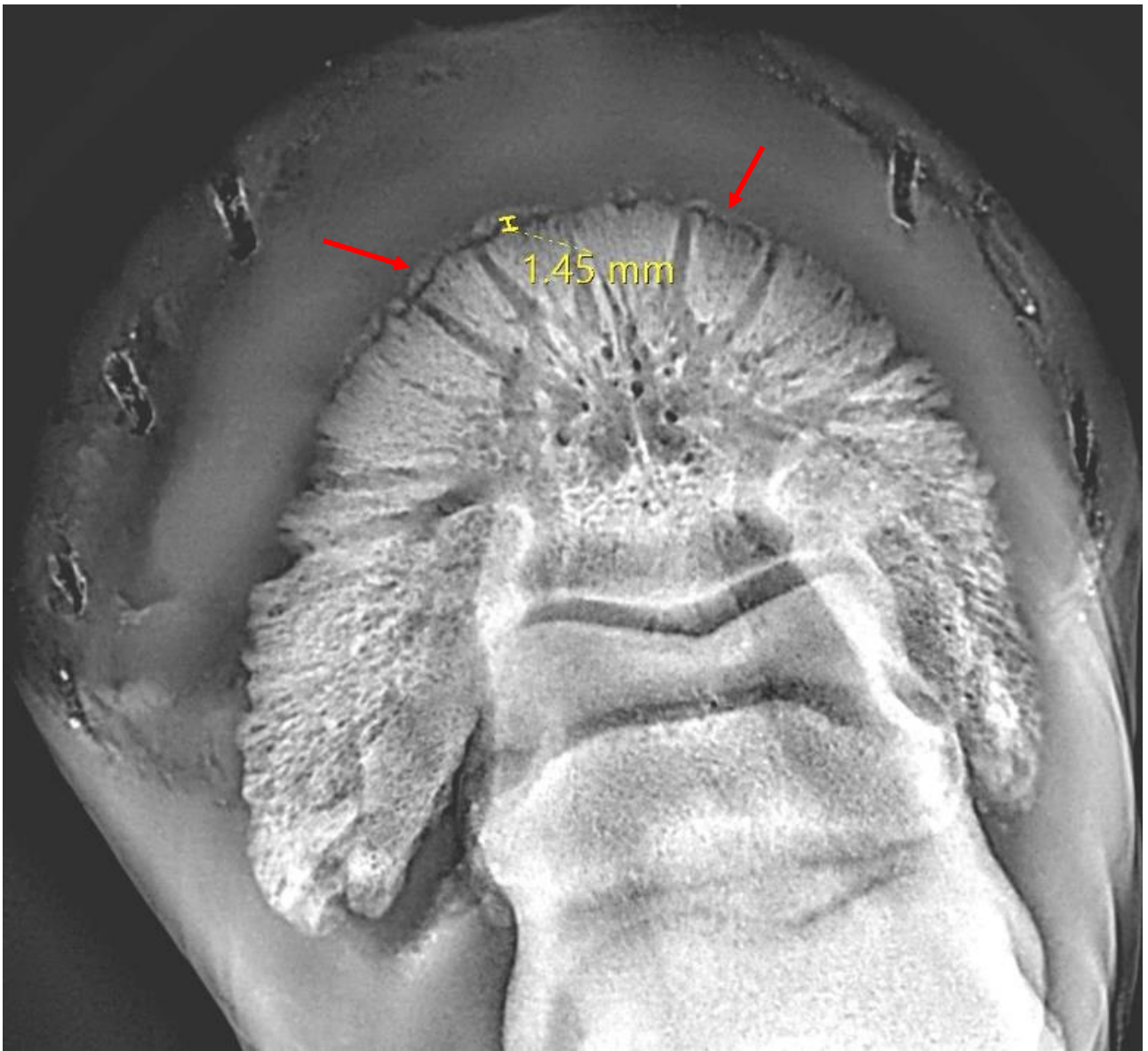Radiographs of the left and right front feet show total resolution of all fractures despite the 1.5mm previous separation of the fracture fragments from the parent bone.



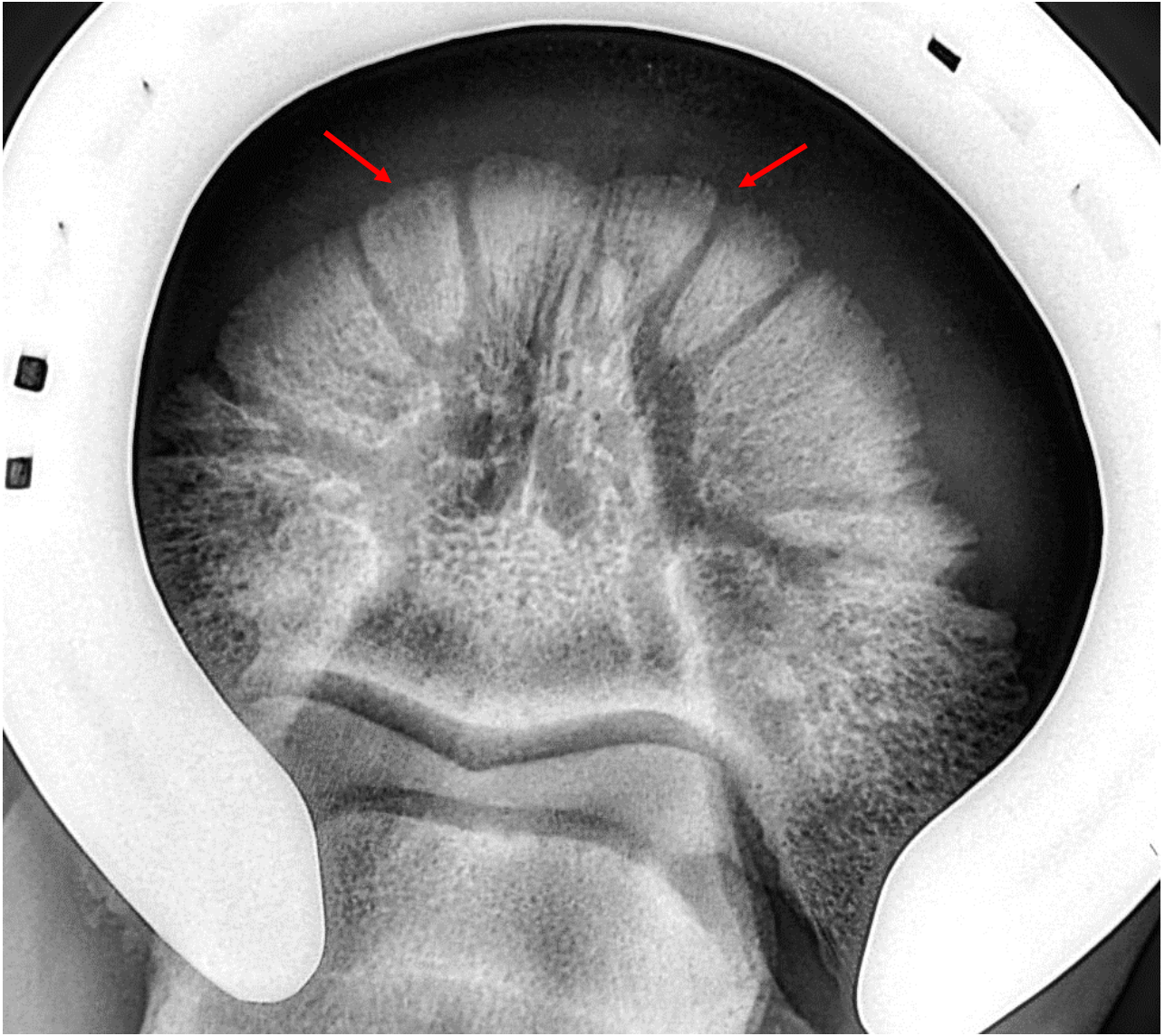
14TH SEP 23 L FR



7TH DEC 23 L FR



14TH SEP 23 R FR



7TH DEC 23 R FR

Comments:

Despite the distraction of the fractures from P3, all fragments have successfully reunited with the P3 margin.

Full resolution of Type IV fractures in a 12 week period is well inside international guides of 6 – 9 months.

Recommendations:

Continue Bone Gold supplementation at 3 x scoops per day while the horse is in work and ensure shoes are well seated out.

Please do not hesitate to contact me if you have any further queries,

Yours Sincerely,

A handwritten signature in dark ink, appearing to read 'A. Watts', is written over a light purple rectangular background.

Dr Andrew Watts B.V.Sc.