



VETERINARY RADIOGRAPHIC REPORT

HORSE: XXXXXXXX

DATES OF EXAMINATION: 26TH AUG 21ST OCT 21 & 17TH NOV '21

PLACE: XXXXXXXXXXXX

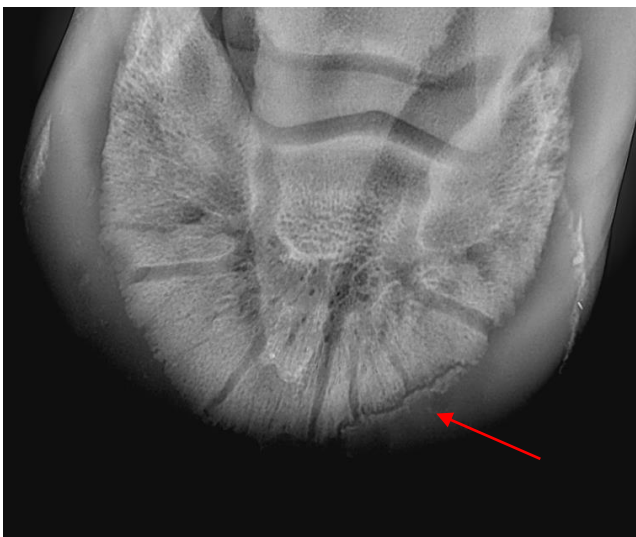
XXXXXXXXXX's left and right front feet were radiographed on 26th Aug 21st Oct (8 weeks) and again on the 17th of Nov '21(12 weeks).

Radiographs:

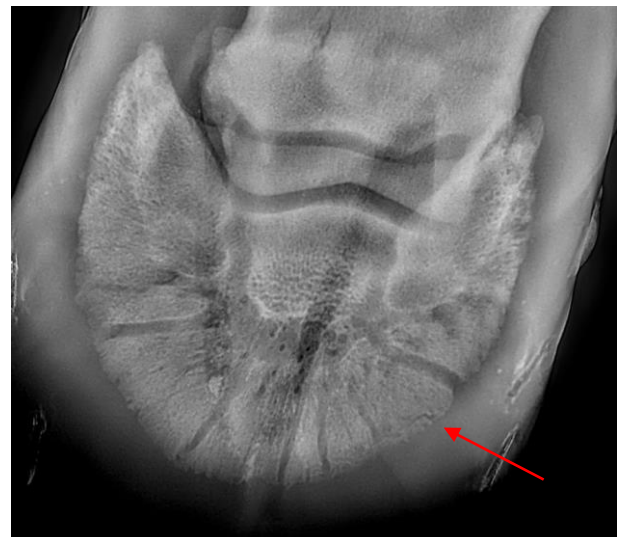26.08.21: Right Front: Large P3 solar margin fracture evident on medial toe 32.6mm x 4.1mm with approximately 1.4mm separation from parent bone as below left image.

21.10.21: Right Front: Fine residual 4.2mm fracture still evident, approximately 90% resolution

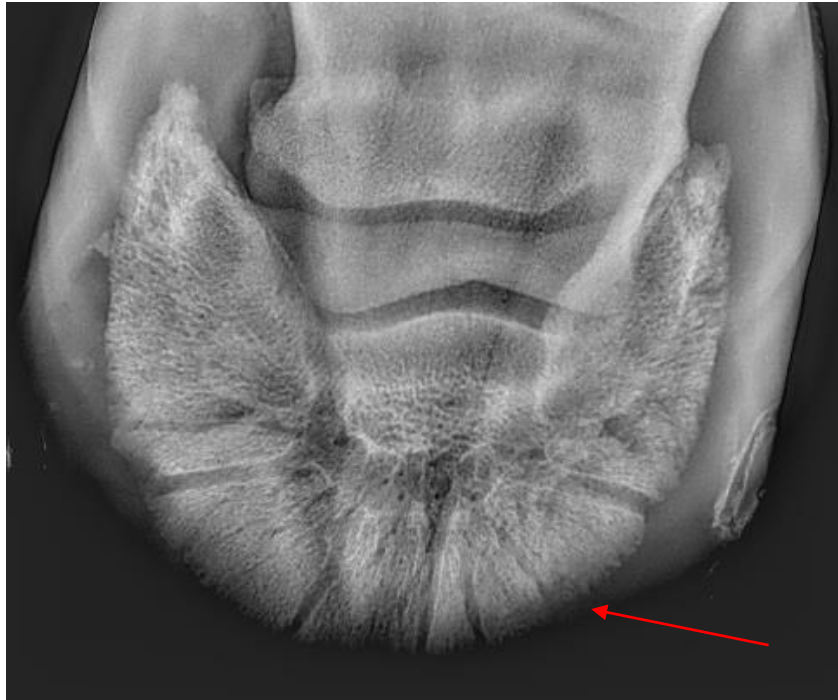17.11.21: Right Front: Fracture fully resolved.



26TH AUG 21



21ST OCT 21



17TH NOV '21

Recommendations:

Radiographic results as of the 17th of Nov '21 show total resolution of the original fracture.

XXXXXXXXX was reshod today utilising off an alloy shoe with a toe clip – inner circumference seated out to avoid any sole pressure.

The horse can return to training.

Continue Bone Gold supplementation at 3 x scoops once per day.

Comments:

Solar margin Type IV fractures of this magnitude have well documented internationally published healing rates of 7 – 12 months. Full resolution of these fractures is rare as most often the fracture fragments are resorbed. Full resolution in a 3-month period was not anticipated. The horse was on Bone Gold 3 x scoops fed once per day for this period.

Please do not hesitate to contact me if you have any further queries.

Yours Sincerely,

A handwritten signature in purple ink, consisting of several overlapping, fluid strokes that form a cursive name.

Dr Andrew Watts B.V.Sc.