



VETERINARY REPORT

HORSE: XXX XXXXXXXXX

DATE OF EXAMINATION: 25TH FEB 2021

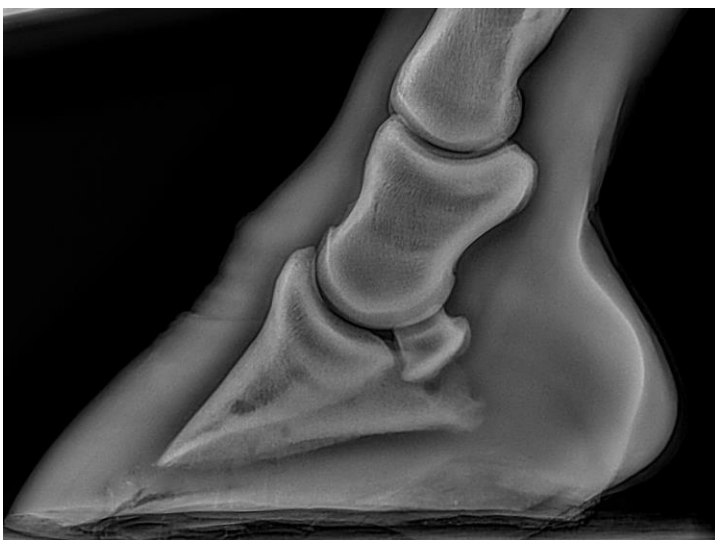
PLACE: XXXXXXXXXX XXXX CANUNGRA

XXX XXXXXXXXXX was examined on 25th Feb and found to be 4/5 lame at the walk left front. Examination revealed a deficit in the sole cranial to the tip of the frog discharging serum. Radiographs were taken showing a 4-degree rotation of P3 in the left with associated acute pedal osteitis and minor demineralisation of P3 solar margin with a clear sub solar gas line on lateral view indicating rotational laminitis. The right front shows no radiographic laminitic changes.

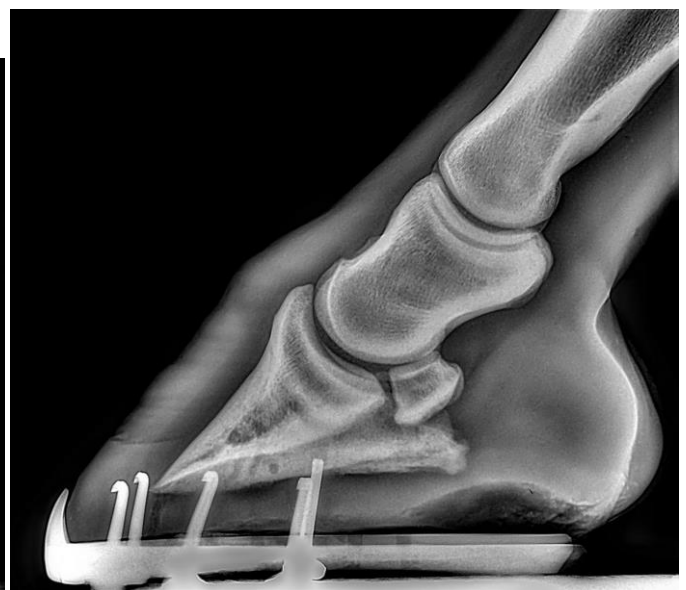The heels were raised with polyurethane and sole packed with the open sole curetted and packed with antibiotics. Post treatment mobility and soundness has improved. The horse will be carefully monitored and kept in box rest with additional radiographs to be retaken in 2 weeks to monitor progress and stabilisation of P3 rotation.

Cause of laminitic incident unknown – possible sequelae to stifle surgery.

Radiographic Examination:



25TH FEB 2021



26TH MAY 2021

Radiographs on the 25th Feb 21 clearly show a rotated P3 with an air pocket continuous from the sole to the ventral extremity of the Pedal bone and approximately 4mm of sole depth despite ventral capsular rupture.

On clinical examination on 26th May XXX XXXXXXXXX presented sound at the trot, sole integrity was excellent and negative to testers.

The ventral sole is beginning to show concavity, wall integrity has improved and approximately 3.12cm of wall growth from the dorsal coronary band was radiographically measured from 25th Feb to 26th May.

Comments:

The recovery time span for the colt has been remarkable.

Initial prognosis for return to racing has reverted from poor to good.

The colt has been on Bone Gold 3 x scoops once per day since initial consultation and should remain on the supplement for 6 months as a prophylactic against potential relapse.

Continue remedial shoeing with core support for 8 weeks.

Thank you for referring XXX XXXXXXXXX, please do not hesitate to contact me if you have any further queries.

Yours Sincerely,

A handwritten signature in purple ink, appearing to read 'A. Watts', is written on a light pink background.

Dr Andrew Watts B.V.Sc.